

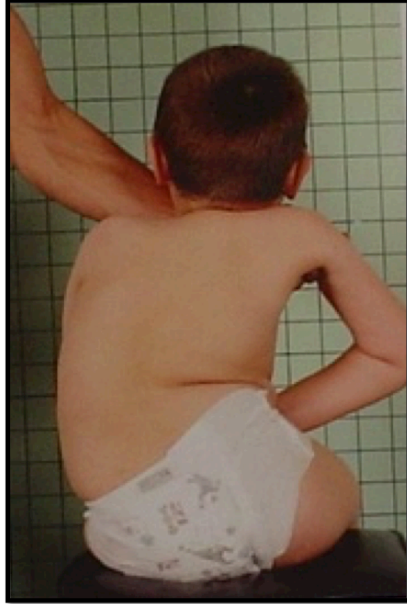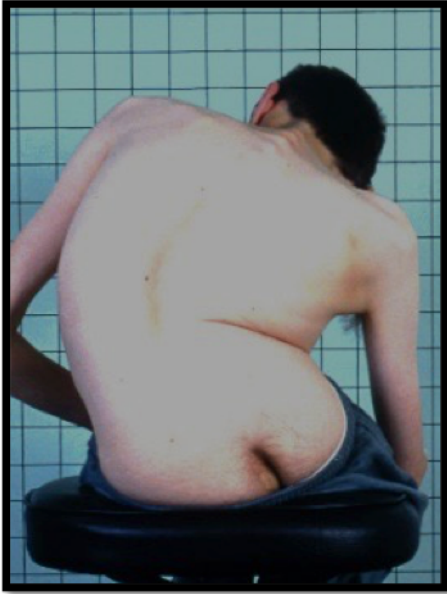NEUROMUSCULAR SCOLIOSIS

A HANDBOOK FOR PATIENTS AND PARENTS

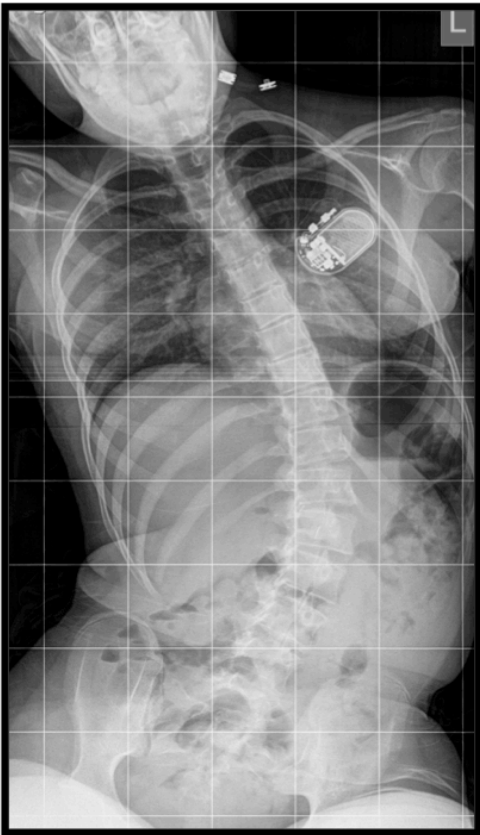Introduction

Neuromuscular scoliosis is a condition that affects children with neuromuscular disorders and is characterized by the presence of one or more abnormal curvatures of the spine. This can be caused in children by very low muscle tone (hypotonia) or in children with a very high muscle tone (spasticity). It also occurs in children with neurological conditions such as muscular dystrophy or spinal muscular atrophy (SMA). Because there is such a wide variety of the types of diseases that may cause neuromuscular scoliosis, the clinical presentation and severity of this condition is extremely variable. Most children with neuromuscular disease have poor balance and poor coordination of their trunk, neck and head. As the children with a neuromuscular condition grow and their trunk muscles get weaker, the spine progressively collapses, producing a long C shaped scoliosis. The curves can also progress during growth spurts. For children who primarily use wheelchairs, severe curves can affect the child's ability to sit comfortably, affecting their quality of life and function. Children with very large curves can develop lung dysfunction, which can lead to recurrent pneumonias (chest infections).

The behavior of neuromuscular scoliosis can be unpredictable. The earlier the curve develops, the more likely it is to progress to a more severe curve. Neuromuscular scoliosis is often associated with a long curve that extends to the pelvis, which causes a condition known as pelvic obliquity, in which the child's pelvis is unevenly tilted with one side positioned higher than the other side. This may result in difficulty sitting, hip problems (subluxation or dislocation) or pressure sores in some cases.



A) Clinical photograph of a patient with cerebral Palsy B) Clinical photograph of a patient with SMA



C) Long C shaped curve characteristic to neuromuscular scoliosis

Classification

Neuromuscular spinal deformities are usually classified into two categories based on the type of disease that the child suffers from:

A. **Neuropathic scoliosis:** This involves diseases that are primarily afflictions of the nervous system. B.

Myopathic scoliosis involves muscle disorders. Many different neuromuscular conditions can lead to neuromuscular scoliosis. They include:

1. Cerebral palsy.
2. Spina bifida (myelomeningocele).
3. Muscular dystrophy
4. Spinal muscle atrophy
5. Mitochondrial disorders
6. Freidreich ataxia
7. Traumatic spinal cord injury.
8. Other conditions

Treatment of Neuromuscular Spinal Deformity

Decisions regarding the appropriate treatment for neuromuscular scoliosis can be difficult, and depend on the severity of the spinal curvature, the age of the patient, the underlying diagnosis, other medical problems, and the goals and wishes of the family.

In neuromuscular scoliosis, curve progression is likely, so most patients and their families will face a choice regarding surgical intervention. Observation, to allow time to follow the natural history of the scoliosis, and to reassess decision-making, is a valid treatment option. In some instances, bracing

may be used to improve seating by providing trunk support, but unfortunately, bracing does not slow progression of this type of scoliosis.

Surgical treatment can allow functional improvements, in terms of ease of daily activities such as eating, dressing, and bathing. It may also provide better sitting balance, decrease the time needed for resting, alleviate discomfort, improve breathing and overall health status, and prevent worsening.

Non-Surgical Treatment

Observation

Observation is a valid option for patients when the natural history of the scoliosis is not clear, when more time may be needed to make decisions, and when the risks of surgery may outweigh the perceived benefits. Observation requires no extra care or expense compared to the patients' current routine.

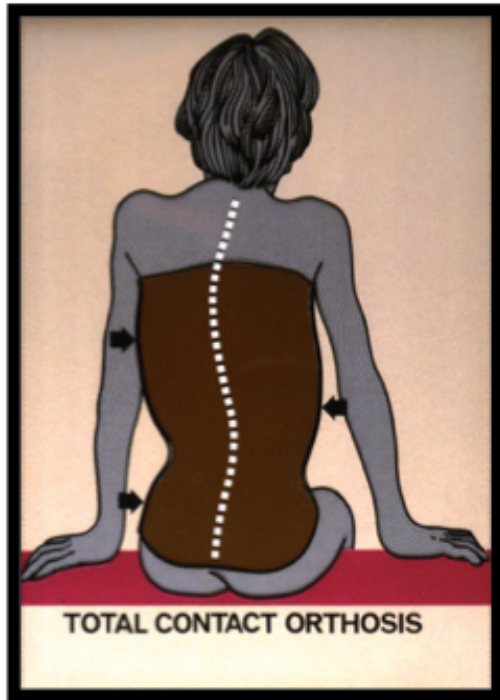Bracing

Bracing for neuromuscular scoliosis may help improve sitting position and provide trunk support. However, there are also some risks. Braces do not permanently straighten these curves, or prevent them from progressing. Some braces may exacerbate pre-existing pulmonary disease if they are too restrictive, and inhibit breathing. Softer materials may be used for braces for neuromuscular patients to avoid these adverse effects.

Wheelchair Modification

Wheelchair modifications may be used to aid seating position and comfort. Custom-molded, padded seats may adapt to patients' bodies, prevent pressure ulcers, and allow

improved upright posture. They share some of the benefits of bracing, but spare the time and difficulty needed to put braces on children. They also share some of the same risks as braces, in that they do not permanently straighten scoliosis, or prevent its progression.



A



B

A: TLSO suitable in some paralytic curves

B: Molded seat insert suitable to spastic type of neuromuscular scoliosis

The Role of Surgical Treatment

Improvements in surgical techniques, intensive care, neurologic, cardiac, and anesthetic techniques now allow surgical solutions for neuromuscular scoliosis, even for fragile patients. However, the complication rates for these surgeries remain significant, and so assessing the expected risks and benefits of surgery for each individual patient is important... Many children with neuromuscular scoliosis

have other underlying medical conditions. It is crucial to understand specific goals for the surgery, which can include better sitting tolerance, better sitting balance, better lung function, less discomfort, better overall health, and the prevention of worsening. Risks from surgery for neuromuscular scoliosis include infection, implant loosening or breakage, progression of a curve despite surgery, back pain, pneumonias, gastrointestinal complications, urinary tract infection, spinal cord injury, or death. Because the complications are substantial, and some complication occurs in about 1 out of every 4 children, the decision making for surgery is complex. The surgeon and the patient's family must work closely together to ensure the correct decision is made for each patient.

Timing of Surgery

When possible, most surgeons prefer to delay spine fusion surgery until the spine and lungs are mostly grown. Fusing the spine prevents further growth and development of the chest, which is not desirable in very young patients. Fusing only the back of the spine in young patients may allow the front of the spine to continue to grow, allowing the deformity to worsen despite the surgery. However, some deformities are difficult to control conservatively, and therefore, early surgery may be justified. In some poorly controlled deformities, rods that allow growth may be useful. These rods are attached only to parts of the spine; with connectors that allow the rods to be lengthened as the spine grows. If lengthenings are needed, they can be done during smaller surgeries every 6 months, or by using an external magnetic device, depending on the situation. A patient with neuromuscular scoliosis must be treated with a team approach. It is very important to treat the entire patient. Close collaboration with therapists, primary care providers, physiatrists, orthotists, nurses, pulmonologists, anesthesiologists, neurologists, and surgeons is essential.

Pre-operative Assessment

The most important part of the decision making process is the preoperative assessment. The surgeon will want to discuss the case with the other physicians involved in your child's care. Consultation with several different types of physicians may be required to ensure that the child is healthy enough to safely undergo the procedure. These physicians may include neurologists, cardiologists, pulmonologists, nutritionists, gastroenterologists, neurosurgeons, anesthesiologists, or others. The other physicians may help assess the child's surgical risk, and may help care for the child before and after surgery.. Other procedures may need to be done prior to spine surgery, such as placing a G-tube for nutrition, or a tracheostomy for pulmonary care, in order to minimize the risks of the procedure.

Risks Related to Surgery

Specific risks related to spine fusion for neuromuscular scoliosis include the following:

Infection: Infection rates after surgery for neuromuscular scoliosis are higher than for other types of scoliosis surgeries, ranging from 4 to as high as 25 out of 100 children. Half are these are superficial, and can be treated with antibiotics. Half are deeper, and require repeat surgery to clean the infection, and possibly implant removal.

Blood Loss: Bleeding can often be significant, and plans for blood management should be established preoperatively. Options may include using a device called a "cell saver" that processes a patient's lost blood so it can be returned to the body, or having units of blood available to be transfused.

Pulmonary Dysfunction: The need to have a breathing tube for respiratory support may last longer than expected. Lung congestion or pneumonias may also develop.

Spinal Cord Injury: There is a small risk of injury to spinal nerves during the surgery which may lead to postoperative weakness, numbness, or dysfunction of the bowels and bladder.. For this reason, many surgeons monitor the spinal cord during the operation, when possible.

Implant Failure: Rarely, the surgical implants may dislodge, or loosen, and require a revision procedure.

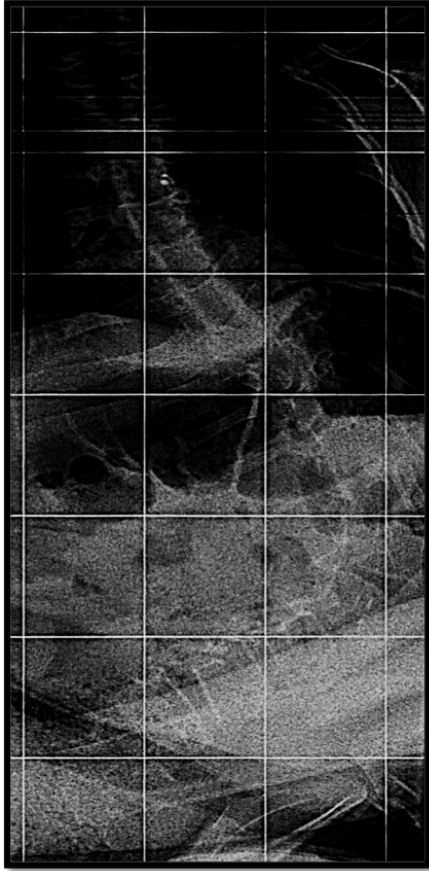
Gastrointestinal Issues: Slowing of bowel function, called constipation or an ileus, may occur due to the stress of surgery, the use of pain medications, or prolonged immobilization. Pancreatitis develops in some patients after surgery, and may require a longer period of not eating after surgery to resolve.

Urinary Tract Infection: About 5 out of 100 patients will have a urinary tract infection after surgery. These can typically be treated and resolved with antibiotics.

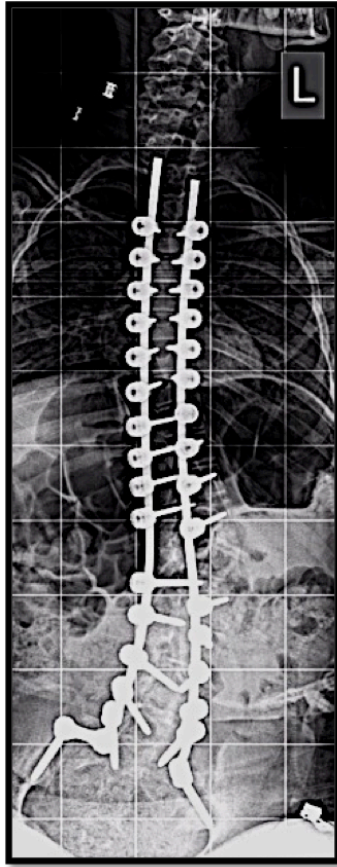
Death: The risk of death within 30 days following neuromuscular scoliosis surgery in the United States is less than 2 out of 100 children. Overall, about 1 out of 4 patients undergoing neuromuscular scoliosis surgery will experience at least one complication. It is imperative that families have a frank discussion with the treating surgeon so that they can understand the risks that pertain to their child and make an informed decision regarding surgical treatment. Most complications are minor or moderate and can be managed fairly easily.

Surgical Techniques

The surgical treatment for neuromuscular scoliosis has evolved over time, and is individualized for each patient. For young patients, growth-friendly surgery can be performed, as discussed in the previous section. For more mature patients, a spinal fusion is required. A spinal fusion involves making an incision in the patient's back, and placing hooks, wires, or screws in the bones as anchors. Metal rods are then attached to the anchors, and are used to straighten the spine as much as possible. Bone graft is then placed over the spine to allow it to fuse. The spine then becomes one solid unit that prevents collapse or further curving. In some cases, the spine is so stiff that the surgeon will perform a surgery from the front of the spine as well. This allows removal of the discs and ligaments between the bones to make the curve more flexible. The front and the back parts of the procedure can be done on separate days, or on the same day in some cases. Traction prior to the spine fusion, during the spine fusion, or bone removal techniques called osteotomies may be helpful in cases with especially large, stiff curves.



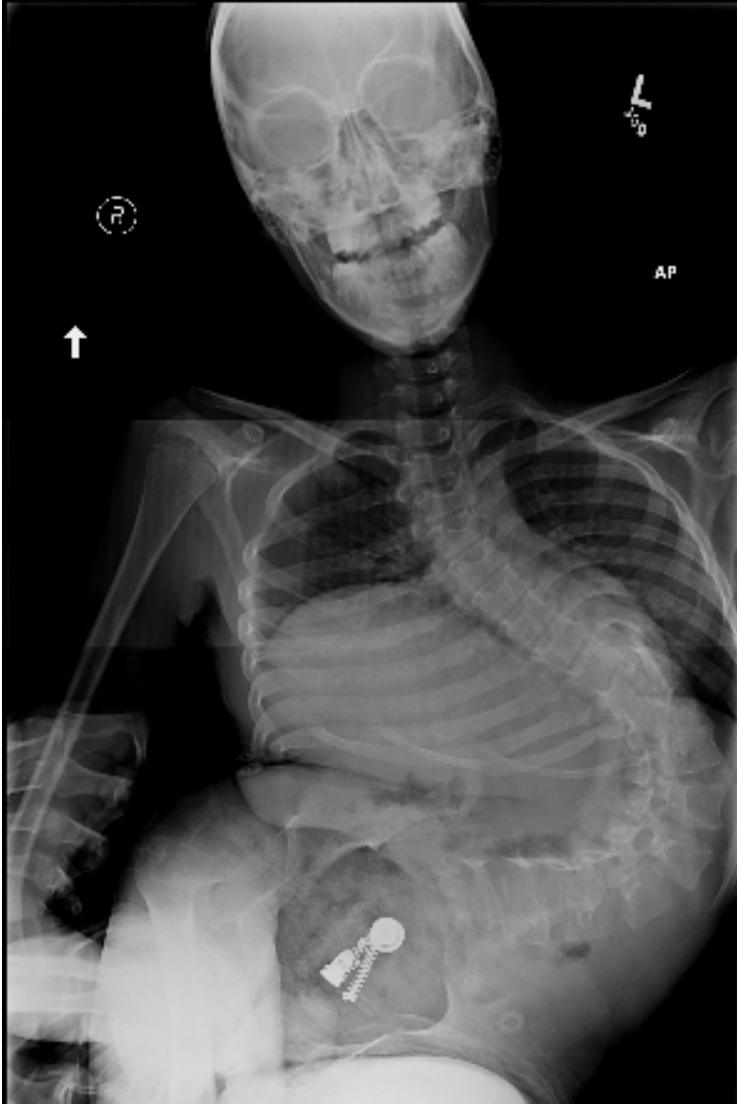A



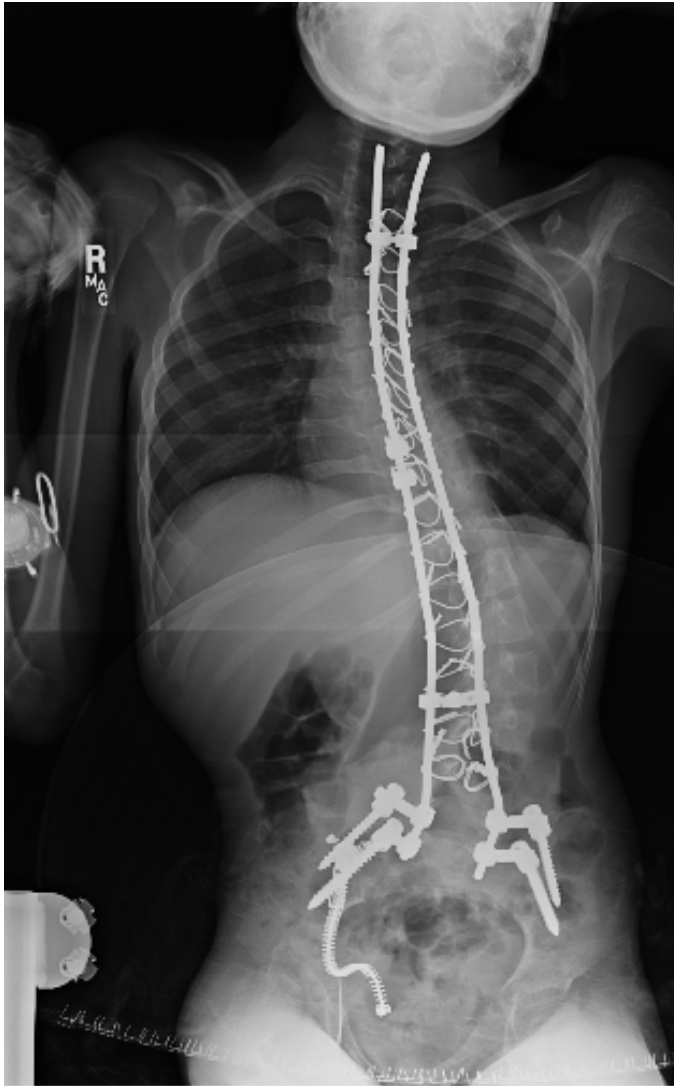
B

A. Pre-op x-ray of a patient with severe scoliosis.

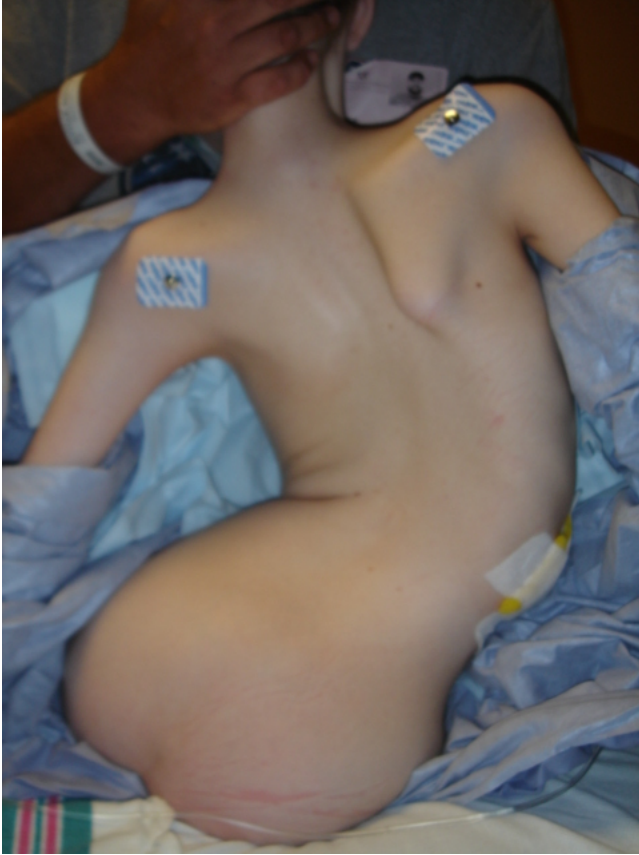B. Post-op x-ray with satisfactory correction of deformity with screws and rods.



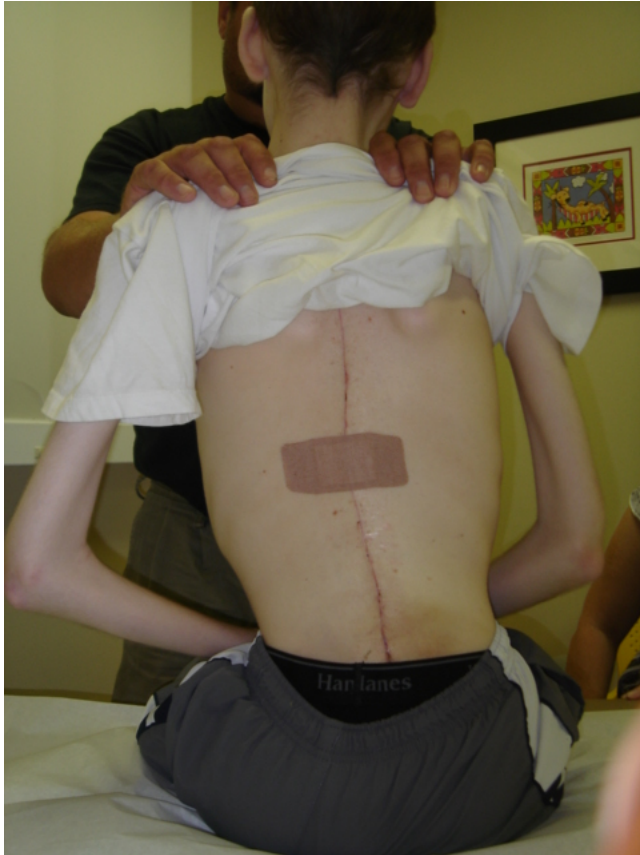Similar patient with severe scoliosis, pre-operative x-rays.



Post-op x-rays of the above patient after instrumentation with rods and wires.



Pre-op photo of a patient with muscular dystrophy.



Post-op photo of the same patient about 2 weeks after surgery

Conclusion

Scoliosis is a common condition seen in patients with neuromuscular disease. The decision to treat the curvature is complex, and must take into account the patient's underlying function, the needs of the patient and family, and the risks specific to that patient. By employing a team approach, to include physicians, other medical caregivers, and the patient's family, it is possible to individualize treatment to provide the best possible outcome for the patient.

